

Topographical Brain Mapping in Depression Following Mild Closed Head Injury: A Case Study

Heath A. Dernaree, W. David Crews, Jr., and David W. Harrison

Previous research (Henriques & Davidson, 1991; Kano, Nakamura, Iida & Nakajima, 1992) supports an association between major depression, reduced beta activity, and heightened alpha activity over the left frontal region relative to the right. A case study of a patient suffering from major depression subsequent to a mild closed head injury tested these hypotheses. A neuropsychological examination of the patient revealed deficits in performance on tasks most sensitive to left frontal functioning. Data obtained using topographical brain mapping showed that the patient had decreased beta and heightened alpha activity over the left frontal region relative to the right, supporting our hypotheses. The use of topographical brain mapping on patients suffering from major depression or mild closed head injury may augment the validity of more traditional neuropsychological assessment techniques.

In recent years, electroencephalographic and neuroimaging techniques have become increasingly popular among researchers for the investigation of the relationship between specific hemispheric asymmetries and clinical depression. These techniques may prove useful tools when used in conjunction with more common neuropsychological tests.

Frontal lobe dysfunction has primarily been identified by neuropsychological tests as integral to depression. Previous research has found impairments among depressives on tests purportedly tapping frontal lobe regions. For instance, depressives have shown impaired performances relative to nondepressives on the Trail Making (Fisher, Sweet & Pfaelzer-Smith, 1986; Shipley, et al., 1981) and Category tests (Savard, Rey & Post, 1980; Watson, Davis & Gasser, 1978) of the Halstead-Reitan Battery. Perseverative errors, thought to be indicative of left and right frontal dysfunction (see Kolb & Wishaw, 1990; Lezak, 1976), have also been associated with depression.

Several electroencephalographic (EEG) studies have examined resting EEG asymmetries in nonpsychotic depressed individuals and found evidence for heightened right frontal lobe activation in depressives, relative to that recorded at their left hemisphere and relative to nondepressed controls (Kano, Nakamura, Matsuoko, Iida & Nakajima, 1992; Schaffer, Davidson & Saron, 1983). For example, in their study of the topographical EEGs of major depression with melancholia Kano, et al. (1992) found evidence for decreased alpha and increased beta activity over the right anterior regions suggestive of heightened right frontal activation in these patients.

Other studies of resting EEG activity have indicated a decreased activation of the left frontal region in depressives as compared to controls (Davidson, 1992; Henriques & Davidson, 1991). Henriques and Davidson (1991) examined alpha band power over the mid-frontal regions and found that *depressives* as compared to nondepressed subjects displayed decreased left-sided activation (i.e. more alpha activity). Otto, Yeo, and Douaher (1987) have theorized that the differential hemispheric activation seen in depression may occur via either an increase in right

hemisphere activity or by a decrease in left hemisphere activity.

Measures of cerebral blood flow (rCBF) have been used to examine hemispheric asymmetries in depressives. For example, Delvenne, Hubain, DeMaertelaer, and Mendlewicz (1990) examined rCBF of major depressives and controls using single photoemission computed tomography (SPECT). Endogenous depressives evidenced significantly lower cortical blood flow in the left hemisphere as compared to controls. Similarly, Mathew, et al. (1980) examined the rCBF of 13 patients with major depression and 13 controls. Depressives exhibited significantly lower cerebral blood flow values for the left hemisphere as compared to controls. Flow values were also negatively correlated with the depth of depression. Together these results indicate hypofusion of the left hemisphere in depression which suggests neural hypoactivity (Mathew, et al., 1980).

Positron emission tomography (PET) has also been employed to examine the glucose metabolic rates in various cerebral regions (Schwartz, Baxter, Mazziotta, Gerner & Phelps, 1987). In their study of cerebral glucose metabolism, Baxter et al. (1989) found that the rate for the left dorsal anterolateral prefrontal cortex divided by the rate for the whole ipsilateral hemisphere in major depressives was significantly lower as compared to controls. There was also a negative correlation between this ratio and depression ratings. Other PET studies have found evidence of decreased rCBF rates in the left anterior cingulate and left dorsolateral prefrontal cortex of major depressives (Bench, et al., 1992; Dolan, et al., 1992). These studies lend additional support for the hypothesis of left frontal dysfunction/hypoactivation in depression.

There has been a relative absence of studies that have examined the hemispheric asymmetries of depressed subjects using topographical brain mapping/computerized electroencephalographic technology. The purpose of this case study was to examine the hemispheric asymmetries, via topographical brain mapping procedures, of a woman with moderate-sever depression and a history of mild closed head injury.

Hypothesis

Predictions derived from previous research (Henriques & Davidson, 1991; Kano, Nakamura, Matsuoko, Iida & Nakajima, 1992) include reduced beta and heightened alpha activity in the left versus the right frontal region.

Method

Subject

The patient was a 29-year-old, married, left-handed, white female who had recently received a formal DSM-III-R (American Psychiatric Association, 1987) diagnosis of major depression from a licensed clinical neuropsychologist. She had previously received her BS degree and was a mother of two young children, ages one and three. The patients Beck Depression Inventory (Beck, 1972) score of 23 placed her within the scale's moderate severe range of depression. At the time of the present study the patient denied any medication or drug usage.

History

The patient was initially referred by her neurologist for a neuropsychological evaluation regarding difficulties that arose subsequent to a head-on motor vehicle accident. She was reportedly wearing seat and chest belts and likely did not hit her head. Although the patient did not recall striking her head during the collision she did report some dizziness immediately following the accident.

The patient described impaired concentration and frequently forgetting what she intended to do. She stated that she frequently would go to get something and subsequently forget what she intended to get. The patient also described herself as saying things differently from what she intended to say. She has decreased her activities and no longer participates in exercise. In general, she describes herself as less able to cope with her children and the demands of being a mother and homemaker.

The patient presented to the neuropsychological assessment complained of impaired concentration, increased irritability, decreased activity level that included occasionally foregoing rehabilitation of back and leg problems (which occurred subsequent to the accident), and a relative inability to cope with her children. The patient also acknowledged a diversity of depressive symptoms that included feelings of sadness, apathy, hopelessness, failure, and guilt, as well as feelings of being punished, heightened disappointment with self, difficulty in making decisions, loss of interest in others, increased irritability and self-criticism, loss of energy, impaired sleep onset and sleep maintenance, heightened fatigue, impaired appetite, worry about physical problems, and decreased libido.

The patient received a comprehensive neuropsychological evaluation that included a neurobehavioral status examination emphasizing hypothesis testing and assessments of sensory, motor, affect, ' memory, spatial awareness, reasoning and intellectual functioning.

Results from the neuropsychological evaluation indicated a pattern of behavioral problems suggestive of neuropsychological deficits principally within the left hemisphere. Specifically, the patient showed impaired sequencing, with numerous perseverative errors on Luria's M & N's and Circle, Square, and Triangle Test; behavioral slowing on the Trails Making Test (A and B), a complex motor sequence task; depression, with decreased facial affective expression; sensitivity to proactive interference on the Rey Auditory Verbal Learning Test; and discoordination on a rapid alternating movement task which was more pronounced when the patient was asked to maintain vigilance to the task across time. The patient's BDI score and self-report during the clinical interview both indicated depression symptomatology. Three out of four neuropsychological tests assessing frontal lobe function indicated mild deficits. The subject denied any other physical problems or past psychological difficulties both during this evaluation and at the time of the present study.

Procedures

The subject was instructed to relax and lie motionless in a supine position on a reclining chair. A

lycra electrode cap was fitted according to the appropriate anatomical marks on the subject's head to measure EEG. The cap was attached via elastic straps to a body harness around the subject's chest to ensure that the cap was securely positioned. EEGs were recorded from 21 scalp locations (Fp1, Fp2, F3, F4, F7, F8, FZ, C3, C4, CZ, T3, T4, T5, T6, P3, P4, PZ, O1, O2) and referenced to the earlobes. Impedance levels at each electrode were measured to be below 10 kOhm. A total of 122, 1second epochs of data were collected for both the eyes open and eyes closed conditions. A sampling rate of 128 was used and frequencies below 2 Hz were eliminated by a high pass filter, thereby substantially reducing low frequency artifact. In each condition, epochs contaminated by eye-blinks and/or movement artifact were also eliminated from the analysis. Twenty-six and thirty-two epochs remained in the eyes open and closed conditions, respectively. The magnitude of the standard alpha (8 to 12 Hz) and beta (12 to 20 Hz) waves of the remaining epochs was assessed using NeuroSearch-24 (Lexicor Medical Technology, 1992).

Results

Topographical brain maps and descriptive data were derived after artifacting the EEG raw data for both the eyes open and eyes closed conditions. Validity of the brain mapping procedure was supported by the subject's decreased relative alpha activity when eyes were open versus closed (See Table 1).

Evidence for heightened left frontal alpha activity (8 to 12 Hz) relative to the right frontal region was found in both the eyes open and closed conditions. Magnitude of alpha and beta activity by frontal region and condition is presented in Table 1.

The subject also showed decreased beta activity (12 to 20 Hz) in the left hemisphere relative to the right during both the eyes open and closed conditions (See Fig. I and Table 1).

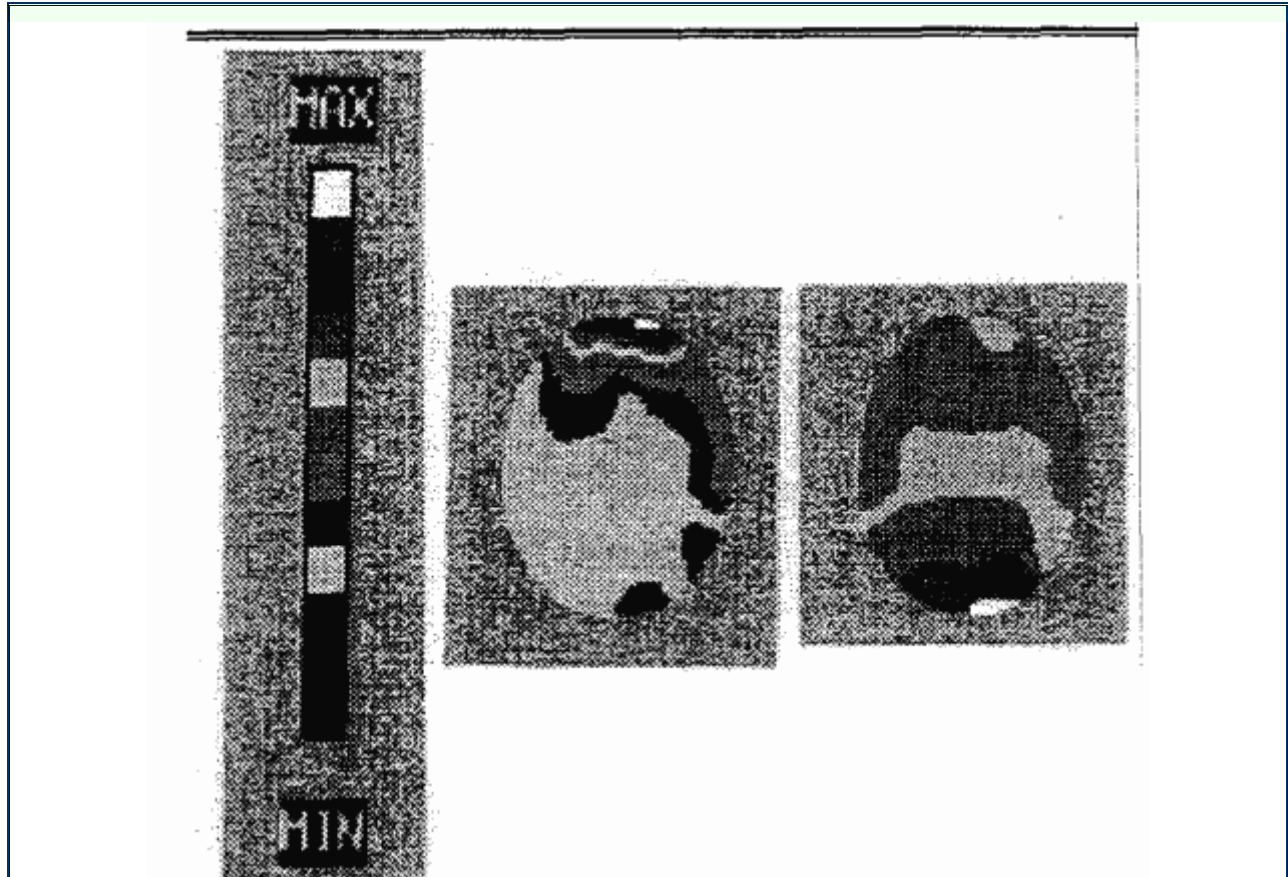


Table 1

Alpha and beta magnitude (pV) in left frontal (Fp1) and right frontal (Fp2) regions in eyes open and closed conditions.

	Eyes open		Eyes closed	
	FP1	FP2	FP1	FP2
Alpha	4.7	4.4	5.6	5.4
Beta	4.6	4.8	3.6	3.8

Figure 1 Beta activity, 12 to 20 Hz, in eyes open (L) and closed (R) conditions.

Discussion

The topographical brain mapping/computerized EEG results from the present study" suggested decreased activation of the left relative to the right frontal cerebral regions., Specifically, the patient exhibited both!! increased alpha activity and decreased beta activity over the left frontal region relative to: the right anterior region. These findings, appear consistent with previous EEG (e.g. , Henriques and Davidson, 1991), SPECT: (Delvenne, et al., 1990; Mathew, et al., 1980),, and PET (Schwartz et al., 1987; Baxter, et al.,: 1989; Bench, et al., 1992; Dolan, et al., 1992) studies which have found evidence for decreased activation of the left anterior cerebrum relative to the right in depressives.

It seems likely that the current subject's, depressive complaints are related to the asymmetry displayed over the frontal brain regions. In particular, the decreased left frontal activation (relative to the right) may allow disinhibition of the right frontal region (Flor-Henry, 1979; Otto, et al., 1987; Swartzburg, 1983), which would presumably affect nonverbal frontal lobe test performance depending on activation level (may improve performances up to a point where further activation may resulting poorer performances), and result in the expression of negative affect and depressive symptomatology similar to what has been observed in several lesion studies (Gainotti, 1972; Sackeim, et al., 1982).

The present results showing decreased left versus right frontal activity may also account for the deficits reported on the subject's neuropsychological evaluation. Deficits in performance were primarily observed on tasks purported to be most sensitive to left frontal functioning. Decreased activation of the left frontal region may have resulted in impaired performance subsequently reflected in the subject's behavioral responses.

Use of topographical brain mapping with patients suffering from major depression and/or mild head injury is supported by this case study. This procedure, when used concurrently with other neuropsychological instruments, may provide improved reliability in assessment. This may be especially important with mild head injury where reliability and cross validation among measures is essential. The use of topographical brain mapping to augment the validity of the more traditional neuropsychological evaluation further provides for the option of pursuing dysfunction using neurotherapies. This may be most promising when neurotherapies rely on idiographic assessment strategies, as was described with this patient.

References

American Psychiatric Association. (1987). *Diagnostic and statistical manual of mental disorders*. (3rd ed., revised). Washington, DC.

Baxter, L. R., Jr., Schwartz, J. M., Phelps, M. E., Mazziotta, J. C., Guze, B. H., Selin, C. E., Germer, R. H., & Sumida, R. M. (1989). Reduction of prefrontal cortex glucose metabolism common to three types of depression. *Archives of General Psychiatry*, 46: 243-250.

Beck, A. T. (1972)- *Depression: causes and treatment*. Philadelphia, PA: Univ. of Pennsylvania Press. Chapter 12.

Bench, C. J., Friston, K. J., Brown, R. G., Scott,

L. C., Frackowiak, R. S. J., & Dolan, R. J. (1992). The anatomy of melancholia -focal abnormalities or cerebral blood flow in major depression. *Psychological Medicine*, 22, 607-615.

- Davidson, R. J. 1992. Anterior asymmetry, affective style and depression. *Psychophysiology*, 29(4A), S4.
- Delvenne, M., Delecluse, F., Hubain, P., Schoutens, A., DeMaertelaer, V., & Mendlewicz, J. (1990). Regional cerebral blood flow in patients with affective disorders. *British Journal of Psychiatry*, 157, 359-365.
- Dolan, R. J., Bench, C. J., Brown, R. G., Scott, L. C., Friston, K. J., & Frackowiak, R. S. J. (1992). Regional cerebral blood flow abnormalities in depressed patients with cognitive impairment. *Journal of Neurology, Neurosurgery, and Psychiatry*, 55, 768-773.
- Fisher, D. G., Sweet, J. J., & Pfaelzer-Smith, E. A. (1986). Influence of depression on repeated neuropsychological testing. *The International Journal of Clinical Neuropsychology*, 8(1), 14-18.
- Flor-Henry, P. (1979). On certain aspects of the localization of the cerebral system regulating and determining emotion. *Biological Psychology*, 14 (4), 677-698.
- Gainotti, G. (1972). Emotional behavior and hemispheric side of lesion. *Cortex*, 8, 41-55.
- Henriques, J. B., & Davidson, R. J. (1991). Left frontal hypoactivation in depression. *Journal of Abnormal Psychology*, 100 (4), 535-545.
- Kano, K., Nakamura, M., Matsuoka, T., Iida, H., & Nakojima, T. (1992). The topographical features of EEGs in patients with affective disorders. *Electroencephalography and Clinical Neurophysiology*, 83, 124-149.
- Kolb, B., & Wishaw, I. Q. (1990). *Fundamentals of human neuropsychology* (3rd ed.). New York: W. H. Freeman & Co.
- Lexicon Medical Technology, Inc. (1992). *NeuroSearch-24: User's manual*. Boulder, CO.
- Lezak, M. D. (1976). *Neuropsychological Assessment*. New York: Oxford University Press.
- Mathew, R. J., Meyer, J. S., Francis, D. J., Semchuk, K. M., Mortel, K., & Claghorn, J. L. (1980). Cerebral blood flow in depression. *American Journal of Psychiatry*, 137 (11), 1449-1450.
- Otto, M. W., Yeo, R. A., & Dougher, M. J. (1987). Right hemisphere involvement in depression: Toward a neuropsychological theory of negative affective experiences. *Biological Psychiatry*, 22, 1201-1215.
- Sackeim, H. A., Greenberg, M. S., Weiman, A. L., Gar, R. C., Hungerbuhler, J. P., & Geschwind, N. (1982). Hemispheric asymmetry in the expression of positive and negative emotions. *Archives of Neurology*, 39, 210-218.
- Savard, R. J., Rey, A. C., & Post, R. M. (1980). Halstead-Reitan category test in bipolar and unipolar affective disorders. *The Journal of Nervous and Mental Disease*, 168(5), 297-304.
- Schaffer, C. E., Davidson, R. J., & Saron, C. (1983). Frontal and parietal electroencephalogram asymmetry in depressed and nondepressed subjects. *Biological Psychiatry*, 18(7), 753-761.
- Schwartz, J. M., Baxter, L. R., Jr., Mazziotta, J. C., Gerner, R. H., & Phelps, M. E. (1987). The differential diagnosis of depression: Relevance of positron emission tomography studies of cerebral glucose metabolism to the bipolar-unipolar dichotomy. *Journal of the American Medical Association*, 258, 1368-1374.
- Shibley, J. E., Kupfer, D. J., Spiker, D. G., Shaw, D. H., Coble, P. A., Neil, J. F., & Cofsky, J. (1981). Neuropsychological assessment and EEG sleep in affective disorders. *Biological Psychiatry*, 16(10), 907-918.
- Swartzburg, M. (1983). Hemispheric laterality and EEG correlates of depression. *Research Communications in Psychology, Psychiatry, and Behavior*, 8(2), 187-205.
- Watson, C. G., Davis, W. E., & Gasser, B. (1978). The separation of organics from depressives with ability- and personality-based tests. *Journal of Clinical Psychology*, 34(2), 393-397.

About the Authors

Heath A. Demaree, M.S., received his MS degree in 1995 from Virginia Polytechnic Institute and State University.

Interested primarily in the cortical, sub cortical, and autonomic correlates of impulsivity, especially in relation to hostility, he is currently working on his Ph.D. in Clinical Psychology.

W. David Crews, Jr. received his Ph.D. in Clinical Psychology from Virginia Polytechnic Institute and State University, Blacksburg, Virginia in 1995 and is completing a residency in Clinical Psychology/Neuropsychology at the University of Virginia Mental Health Sciences Center, Charlottesville, Virginia.

Dr. David W. Harrison, Ph.D., received his Ph.D. in 1983 and completed his postdoctoral fellowship in 1985 at the University of Georgia at Athens. He currently is associate professor at Virginia Polytechnic Institute in Blacksburg, VA. Address correspondence to: David W. Harrison, Ph.D., Department of Psychology, Virginia Polytechnic Institute and State University, Blacksburg, Virginia 24061, U.S.A.